

# Current and Future Strategies in Radiotherapy of Childhood Low-Grade Glioma of the Brain

## Part I: Treatment Modalities of Radiation Therapy

Rolf-Dieter Kortmann<sup>1</sup>, Beate Timmermann<sup>1</sup>, Roger E. Taylor<sup>2</sup>, Giovanni Scanzello<sup>3</sup>, Ludwig Plasswilm<sup>1</sup>, Frank Paulsen<sup>1</sup>, Branislav Jeremic<sup>1</sup>, Astrid K. Gnekow<sup>4</sup>, Karin Dieckmann<sup>5</sup>, Sylvia Kay<sup>1</sup>, Michael Bamberg<sup>1</sup>

**Background:** Treatment of childhood low-grade gliomas is a challenging issue owing to their low incidence and the lack of consensus about "optimal" treatment approach.

**Material and Methods:** Reports in the literature spanning 60 years of radiation therapy, including orthovoltage, megavoltage and recently modern high-precision treatments, were reviewed with respect to visual function, survival, prognostic factors, dose prescriptions, target volumes, and treatment techniques. Based on these experiences, future strategies in the management of childhood low-grade glioma are presented.

**Results:** Evaluation of published reports is difficult because of inconsistencies in data presentation, relatively short follow-up in some series and failure to present findings and results in a comparable way. Even with the shortcomings of the reports available in the literature, primarily concerning indications, age at treatment, dose response, timing and use of "optimal" treatment fields, radiation therapy continues to play an important role in the management of these tumors achieving long-term survival rates up to 80% or more. Particularly in gliomas of the visual pathway, high local tumor control and improved or stable visual function is achieved in approximately 90% of cases. Data on dose-response relationships recommend dose prescriptions between 45 and 54 Gy with standard fractionation. There is consensus now to employ radiation therapy in older children in case of progressive disease only, regardless of tumor location and histologic subtype. In younger children, the role of radiotherapy is unclear. Recent advances in treatment techniques, such as 3-D treatment planning and various "high-precision" treatments achieved promising initial outcome, however with limited patient numbers and short follow-ups.

**Conclusions:** Radiation therapy is an effective treatment modality in children with low-grade glioma regarding tumor control and improvement and/or preservation of neurologic function or vision, respectively. More prospective studies are needed to address the impact of modern radiation therapy technologies (including intensity-modulated radiotherapy) on outcome especially in the very young and to define the role of radiation therapy as a part of a comprehensive treatment approach. The forthcoming prospective trial SIOP/GPOH LGG RT 2003 is addressing this issue.

**Key Words:** Low-grade glioma · Children · Radiation therapy · Surgery

Strahlenther Onkol 2003;179:509–20

DOI 10.1007/s00066-003-9104-9

### Aktuelle und zukünftige Strategien bei der Bestrahlung von niedrigmalignen Gliomen des Gehirns im Kindesalter. Teil I: Strahlentherapeutische Behandlungsmodalitäten

**Hintergrund:** Die Behandlung maligner Gliome im Kindesalter ist wegen deren geringer Häufigkeit und Kontroversen über optimale Behandlungsstrategien eine Herausforderung an den Radioonkologen.

**Material und Methodik:** Es wurden Berichte in der Literatur, die 60 Jahre Strahlentherapie von Orthovolt- sowie Megavolttechniken bis zu den heute modernen Präzisionstechniken umfassen, analysiert. Basierend auf diesen Erfahrungen werden zukünftige Strategien bei der Behandlung niedrigmaligner Gliome im Kindesalter vorgelegt.

**Ergebnisse:** Die Evaluierung publizierter Berichte ist aufgrund heterogener Aufarbeitung der Daten, teilweise kurzer Nachbeobachtungszeiträume und fehlender Darstellung der Ergebnisse in vergleichbarer Form erschwert. Trotz begrenzter Aussagekraft der Literaturangaben, die in erster Linie die Indikationen, das Behandlungsalter, Dosis-Wirkungs-Beziehungen, den Zeitpunkt der Bestrahlung und die Anwendung optimaler Bestrahlungsfelder betreffen, spielt die Strahlentherapie unverändert eine wichtige Rol-

<sup>1</sup> Department of Radiooncology, University of Tübingen, Germany,

<sup>2</sup> Radiotherapy Department, Cookridge Hospital, Leeds, United Kingdom,

<sup>3</sup> Department of Radiotherapy, Padua General Hospital, Italy,

<sup>4</sup> Children's Hospital, Augsburg, Germany,

<sup>5</sup> Department of Radiooncology, General Hospital Vienna, Austria.

Received: October 16, 2002; accepted: May 6, 2003

le bei der Therapie dieser Tumoren und erreicht langfristige Überlebensraten von 80% und mehr. Insbesondere bei Gliomen der Sehbahn werden in annähernd 90% der Fälle eine hohe lokale Tumorkontrolle und ein verbessertes oder stabilisiertes Sehvermögen erreicht. Nach Erfahrungen über Dosis-Wirkungs-Beziehungen werden Dosierungen zwischen 45 und 54 Gy in konventioneller Fraktionierung empfohlen. Es besteht heute Übereinstimmung, bei älteren Kindern die Strahlentherapie nur im Fall einer Tumordprogression unabhängig von Tumorlokalisierung oder histologischem Subtyp zu beginnen. Bei jüngeren Kindern ist die Rolle der Strahlentherapie unklar. Aktuell werden chemotherapeutische Protokolle untersucht, um die Strahlentherapie mit dem Ziel hinauszuzögern, potentiell schwerwiegende Therapiefolgen zu reduzieren. Aktuelle Fortschritte bei Bestrahlungstechniken wie 3-D-Bestrahlungsplanung und unterschiedlichen Hochpräzisionstechniken erreichten viel versprechende klinische Ergebnisse bei jedoch begrenzten Patientenzahlen und kurzen Nachbeobachtungszeiträumen.

**Schlussfolgerungen:** Die Strahlentherapie ist eine effektive Behandlungsmodalität bei Kindern mit niedrigmalignen Gliomen hinsichtlich Tumorkontrolle und Verbesserung oder Erhalt neurologischer Funktionen oder des Sehvermögens. Prospektive Studien, die die Bedeutung moderner Bestrahlungstechniken (unter Einschluss intensitätsmodulierter Bestrahlung) für das klinische Ergebnis, besonders bei kleinen Kindern, beinhalten, sind notwendig, um den Stellenwert der Strahlentherapie innerhalb eines umfassenden Behandlungskonzeptes zu untersuchen. Die zukünftige prospektive Studie der SIOP/GPOH LGG RT 2003 greift dieses Thema auf.

**Schlüsselwörter:** Niedrigmaligne Gliome · Kinder · Strahlentherapie · Operation

### Introduction

Low-grade gliomas in children predominantly arise along the visual pathway with or without involvement of the hypothalamus, followed in frequency by the cerebral hemispheres and the posterior fossa. Their biological behavior varies greatly: even small chiasmatic tumors may display an aggressive, malignant growth pattern causing rapid visual deterioration, progressive neurologic deficits and diencephalic syndrome, whereas larger tumors may remain quiescent for years.

Recent advances in neurosurgery, radiation techniques and the introduction of chemotherapy have opened up new possibilities but have also introduced controversies in the optimal management of childhood low-grade gliomas. Numerous reports addressed these questions favoring one or another approach, identified possible prognostic factors and suggested “optimal” treatment approach based on these factors [3, 5, 8, 14–18, 31–33, 35, 36, 40, 52–55, 57, 74, 76, 77]. Unfortunately, all of these studies were retrospective, spanning long time periods during which diagnostic and therapeutic variables changed considerably.

This review is, therefore, undertaken to offer better insight in the radiotherapy treatment parameters and treatment outcome, while the second part of this review will focus on radiotherapy-related toxicity. Medline search was performed for publications including case reports and supplements on radiotherapy in the management of gliomas of the visual pathway from 1956 and 2001. The literature was reviewed with respect to visual function, survival, prognostic factors, dose prescriptions, target volumes, and treatment techniques. Conclusions were drawn from the data on future radiotherapeutic treatment strategies.

### Hemispheric Gliomas

Low-grade gliomas of the cerebral hemispheres in children generally carry an excellent long-time prognosis, because dis-

ease progression is rarely observed after complete resection [16, 18, 55, 68]. Extent of resection is the factor associated most strongly with progression-free survival favoring complete tumor removal. Pollack et al. [55] observed no disease progression in 21 patients who underwent a complete tumor resection, compared to two of twelve (17%) undergoing nearly complete resections and eleven of 37 (30%) undergoing subtotal resections. However, even with incomplete tumor removal prolonged progression-free survival is commonly achieved [18]. In an analysis of 51 patients with supratentorial pilocytic astrocytoma, for 16 patients undergoing complete resection the 10-year survival rate was 100%, while it was 74% for 35 patients who had subtotal removal or biopsy [18]. Fisher et al. [16] observed a 5- and 10-year progression-free survival rate of 100% in 25 children in whom a complete tumor resection was possible. Radiotherapy offers an additional benefit by improving focal neurologic deficits. In the series of Fischer et al. [15], nine of 15 children demonstrated focal neurologic disorders before receiving radiotherapy, and seven of these nine patients showed significant improvement.

### Gliomas of the Cerebellum

Among the 45–60% of infratentorial pediatric brain tumors, cerebellar astrocytoma ranks second to medulloblastoma in frequency [50]. Surgery plays the key role. Complete surgical resection, as judged by postoperative neuroimaging and operative record, appears possible in 84–90% of all patients [21]. Extended periods of stable disease, and sporadic cases of tumor regression, following partial resection are reported for small numbers of patients [10, 27, 61]. However, for the majority of cases residual tumor tends to progress over long periods of time, mostly within 4–5 years after initial operation, and progression-free survival rates are between 29–80% and 0–79% at 5 and 10 years [10, 24, 27, 61, 64].

### Gliomas of the Supratentorial Midline (Visual Pathway and Hypothalamus)

These usually grow slowly but their pathobiological behavior may vary considerably. The infiltrating growth pattern and involvement of functionally significant areas may result in progressive loss of vision and hypothalamic damage precluding radical surgery. Several series have demonstrated a poor outcome in patients with chiasmal tumor managed conservatively without radiation. In the report by Tenny et al. [71] only three of 14 (21%) survived after biopsy or exploration only, compared to 28 of 44 (64%) who received radiotherapy. In the series of Montgomery et al. [52] of 16 patients undergoing radiation therapy, twelve patients were alive without evidence of

disease at a mean follow-up of 6.3 years. The importance of histologic confirmation of optic gliomas must be weighed against the potential morbidity from surgery for obtaining tissue. A decrease in visual function was reported after surgical procedure in 43% of patients by Danoff et al. [8] and 75% by Montgomery et al. [52]. Histologic confirmation may not be necessary, if course of disease and imaging provide evidence for a diagnosis of a glioma.

#### Impact on Visual Function

Radiotherapy has become a standard treatment of optic nerve and chiasmal gliomas since Taveras et al. [70] reported improvement in visual acuity in eleven of 22 patients without noting any morbidity associated with irradiation. Numerous reports over the years consistently support the high efficacy (90%) of radiotherapy in stabilization and improvement of visual function [3, 6, 8, 11, 14, 17, 31–33, 37, 52, 54, 57, 69, 70, 76, 77] (Table 1). In contrast to these studies, Dutton in his analysis of 1,136 patients failed to confirm a benefit of radiotherapy [13]. Among 511 patients treated with radiotherapy and followed for up to 10 years, 354 (69%) showed stable or improved vision. 203 similar patients were followed without radiotherapy. 156 (77%) showed visual stability or improvement. However, the comparisons are biased because a conservative approach without treatment can be assumed in the majority of patients with clinically stable tumors, whereas the proportion of patients with progressive tumors will probably be higher in the cohort undergoing radiotherapy.

#### Prognostic Factors

**Tumor Location.** Impact of tumor location within the visual pathway on survival has been frequently investigated. In the study of Wong et al. [77], 38 cases of optic gliomas were reviewed. 24 patients had radiotherapy as part of the initial treatment. 10-year survival and relapse-free survival rates were 87% and 55%, respectively. Gliomas of the optic chiasm had a poorer prognosis with a 56% recurrence rate for chiasmal tumors versus 22% for tumors confined to the optic nerve. Rush et al. [58] demonstrated adverse influence of tumor involvement of optic chiasm and/or hypothalamus. The long-term survival rate

**Table 1.** Visual function/visual field (Vis. field) after radiotherapy of gliomas of the optic pathway. n.m.: not mentioned.

**Tabelle 1.** Visusfunktion/Gesichtsfeld (Vis. field) nach Bestrahlung von niedrigmalignen Gliomen im Kindesalter. n.m.: nicht erwähnt.

Author	n	Total dose <sup>a</sup>	Improved	Stable	Worse
Taveras et al., 1956 [70]	22	8–15 Gy	Vision 11	8	3
Montgomery et al., 1977 [52]	12	35–65 Gy (almost all 50 Gy).	Vision 3	9	0
Hoyt & Baghdassarian, 1969 [33]	28	n.m.	Acuity 4	18	6
Dosoretz et al., 1980 [11]	9	37–55.8 Gy	Vision 1	8	0
Kalifa et al., 1981 [37]	39	50–60 Gy	Vision 7	30	2
Horwich & Bloom, 1985 [32]	23	45–50 Gy	Acuity (23) 10 Vis. field (23) 4	11 19	2 0
Danoff et al., 1980 [8]	18	50–60 Gy	Vision 6	8	4
Weiss et al., 1987 [76]	12	40–56 Gy	Vision 3	9	0
Flickinger et al., 1988 [17] <sup>b</sup>	22	38–56.86 Gy	2	14	3
Wong et al., 1987 [77]	17	35–61 Gy	6	9	2
Pierce et al., 1990 [54] <sup>b</sup>	23	45–56.6 Gy	23	14	2
Rodriguez et al., 1990 [57] <sup>b</sup>	15	43–60 Gy	Vision 3	8	1
Bataini et al., 1991 [3] <sup>b</sup>	44	40–60 Gy	Acuity 25 Vis. field 19	16 11	3 1
Tao et al., 1997 [69] <sup>b</sup>	29	50.4–55.8 Gy	Vision 7	14	5
Erkal et al., 1997 [14] <sup>b</sup>	13	40–60 Gy	9	14	3
Cappelli et al., 1998 [6]	54	n.m.	Vision 18	29	7
Grabenbauer et al., 2000 [31]	25	45–60 Gy	Acuity (25) 9 Vis. field (20) 3	13 16	3 1

<sup>a</sup>In the majority of cases, the fractionated dose ranged between 1.5 and 2.0 Gy; <sup>b</sup>no data for remaining patients

was 85% for 33 patients with tumors of the optic nerve, compared to 44% in 52 patients with tumors involving the optic chiasm. Almost all patients (93%) with chiasmal tumors died of tumor progression.

Kovalic et al. [45] treated 33 patients with optic nerve and chiasmal gliomas. Tumor-related mortality rate was 6% at 5 years, 19% at 10 years, and 26% at 15 years. Posttreatment progression over 15 years was not observed in patients with tumors confined to the optic nerve, but was noted in five patients (14%) with chiasmal tumors, and in 14 patients (43%) with chiasmal lesions with invasion of the adjacent midbrain. Survival rates at 5, 10, and 15 years were 94%, 81%, and 74%, respectively, and corresponding progression-free survival rates were 85%, 75%, and 75%, respectively. There was no difference between children undergoing surgery followed by radiotherapy and those receiving radiotherapy alone.

In the series of Bataini et al. [3], 57 patients with optic gliomas received radiation therapy. Local control of disease was obtained in 45 patients (85%). The overall actuarial survival rate was 83.5% at 5 and 10 years. Corresponding relapse-free survival rates were 89% and 82%. In gliomas involving the anterior chiasm (21 patients), relapse-free survival rates were 100% and 88% at 5 and 10 years, respectively. In gliomas extending beyond the chiasm and accompanying involvement of hypothalamic structures (36 patients), the corresponding relapse free survival rates were 82% and 72%. Other authors, however, could not confirm these observations. Erkal et al. [14] followed 33 children with gliomas of the anterior optic pathway and hypothalamus treated with radiotherapy at time of diagnosis. Progression-free and overall survival rates at 5 and 10 years were 82%/93% and 77%/79%, respectively. No difference between gliomas of the anterior visual pathway and gliomas with involvement of the hypothalamus could be detected, which was confirmed by Grabenbauer et al. [31].

*Neurofibromatosis.* The prognostic value of neurofibromatosis (NF) is unclear. The contribution of patients with NF undergoing radiation therapy varies in the literature between 10% and > 50% [3, 6, 8, 14, 31, 35, 36, 45, 54, 57, 69, 77]. Frequently, survival of patients with NF was not separately analyzed, and often results are inconclusive.

Kovalic et al. [45] treated eleven patients with NF and compared outcome with 22 patients without NF. The 5-, 10-, and 15-year progression-free survival rates for the NF patients were 90%, 70%, and 70%, respectively, as compared to 76% for all time intervals for the NF-negative cohort without finding a statistical difference. Jenkin et al. [36] compared 38 NF patients with 49 patients without NF and found a statistically significant difference in relapse-free survival rates in favor of NF patients (89%, 89%, and 84% at 5, 10, and 15 years, respectively) as compared to NF-negative patients (56%, 50%, and 47%, respectively). However, the advantage in relapse-free survival was not translated into overall survival. Cappelli et al. [6] found a better survival in NF patients, but without noting a statistically significant difference. In the series of

Chan et al. [7], the presence of NF was associated with an increased relapse-free survival. In the series of Janss et al. [35], tumor progression was less common in NF-positive patients who underwent first-line chemotherapy followed by radiotherapy in case of failure of chemotherapy. Tumors of two of 15 patients with NF progressed during follow-up as compared to 21 cases in 31 patients without NF. The differences were statistically significant. Grabenbauer et al. [31] could confirm this observation, however, in three patients only. No progression was noted after 10 years in patients with NF as compared to 82% progression-free survival in 22 patients without NF.

Other authors, however, did not find a survival advantage for patients with NF [14].

*Other Prognostic Factors.* Detrimental effects of tumor on neurologic function appear to be of prognostic relevance. In the series of Bataini et al. [3], patients with neurologic signs at time of treatment achieved poorer survival rates: 57% versus 92% in the absence of neurologic signs at 5 and 10 years, respectively. Grabenbauer et al. [31] noted a significant impact on progression-free survival for age at diagnosis. For patients  $\leq 10$  years of age at the time of radiotherapy, a 10-year progression-free survival of 51% was found as compared to 91% for patients  $> 10$  years. Kovalic et al. [45] found a significantly better progression-free survival rate for patients  $> 15$  years (71% vs. 88% at 10 years). Jenkin et al. [36] in their large series, however, could not confirm these observations. Other possible prognostic factors such as presence of hydrocephalus and extent of resection could not be confirmed in uni- or multivariate analysis in series of other authors [31, 36, 45].

#### Timing of Postoperative Radiotherapy

Several retrospective studies have indicated an advantage for immediate postoperative radiotherapy regarding overall survival and progression-free survival in adults [23, 62, 63], although there are opposite observations [30]. Recent results of an EORTC/MRC study have shown that immediate postoperative radiotherapy in low-grade glioma improved progression-free survival over that seen with observation only (5-year progression-free survival rates: 44% vs. 37%;  $p = 0.02$ ). This benefit, however, was not translated into an improvement in overall survival [38].

#### Hemispheric and Cerebellar Low-Grade Gliomas

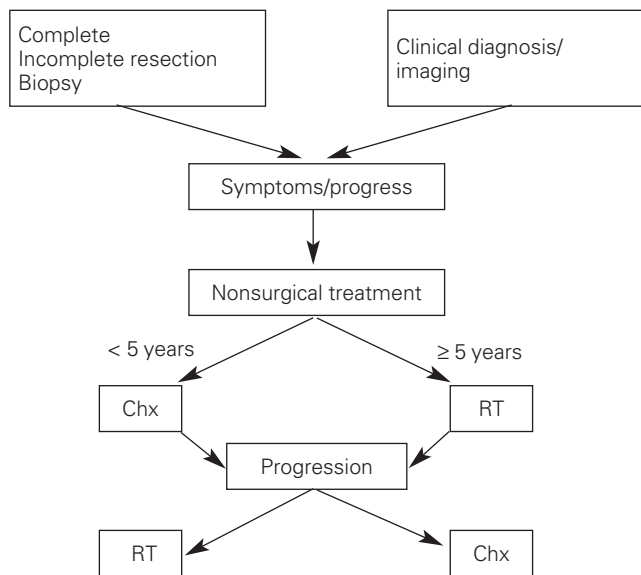
In children, in the series of Pollack et al. [55], immediate postoperative radiotherapy after subtotal resection in 33 patients yielded a 10-year progression-free survival rate of 82% as compared to 40% in 16 patients not receiving immediate postoperative radiotherapy ( $p = 0.014$ ). Forsyth et al. [18] observed that immediate postoperative radiotherapy had an impact on overall survival in 39 patients with supratentorial pilocytic astrocytoma who received postoperative radiation therapy. Fisher et al. [16] retrospectively analyzed the policy of surveillance alone after surgery in 128 children. The median follow-up was 7.3 years. After complete resection no recurrence was

observed. 48 patients received immediate postoperative irradiation after incomplete resection and twelve (25%) relapsed, whereas the rate of tumor progression among 55 patients in whom radiotherapy was deferred was 42%. The corresponding 5- and 10-year progression-free survival rates were 81%/68% versus 69%/55%. However, as noted in adults, the results were not translated into overall survival with rates at 5 and 10 years of 81%/73% versus 87%/83% for those patients not receiving immediate radiotherapy.

Postoperative radiotherapy has been employed for patients with residual, progressive or recurrent cerebellar astrocytoma in a rather unsystematic pattern. Garcia et al. [24] noted that of 21 patients locally controlled after incomplete resection 16 were irradiated. In a previous analysis on the same patients, the cohort of 26 patients receiving immediate radiotherapy experienced a prolonged progression-free survival which was translated into a trend toward a better overall survival as compared to 16 patients undergoing surgery alone (70% vs. 60% survival rate) [25]. In other series, however, this observation could not be confirmed [10, 27, 61, 64].

#### Low-Grade Gliomas of the Supratentorial Midline (Visual Pathway)

Jenkin et al. [36] addressed this question in a retrospective analysis. 38 patients received postoperative radiotherapy while 49 underwent surveillance. No difference in progression-free and overall survival rates could be detected (65% vs. 65% and 69% vs. 80% at 15 years), although more residual disease in the radiotherapy group may have adversely influenced outcome. In the study from St. Jude's hospital, radiotherapy was used only in case of progressive disease [21]. 107 out of 142 children with tumors of all sites were observed, while 31 patients received radiotherapy and four chemotherapy (they were < 5 years of age), respectively, when showing progressive disease. The progression-free survival and overall survival rates of all patients were 70% and 90%, respectively, whereas the overall survival rate was only 65% at 4 years in children after treatment for progressive disease. By contrast, in the series of 29 patients reported by Tao et al. [69], the policy to treat with radiation therapy as determined by clinical progression or increase in tumor size on imaging achieved a better result with a 15-year progression-free survival rate of 82.1% and overall survival rate of 85.1%. The strategy to postpone the necessity for radiotherapy until time to progression is investigated in the ongoing prospective SIOP/GPOH LGG trial (Figure 1). Children  $\geq 5$  years of age receive radiotherapy as first-line nonsurgical treatment, whereas children aged < 5 years receive chemotherapy in progressive disease. The dose prescription for radiotherapy is 54 Gy with 1.8 Gy fractionated dose to the tumor site. Chemotherapy consists of carboplatin and vincristine. Preliminary data in 96 patients show that a 3-year progression-free survival rate of 87.1% and an overall survival rate of 95.7% can be obtained by radiotherapy at a median follow-up of 90 months



**Figure 1.** Design of the ongoing SIOP/GPOH LGG trial (GPOH: Deutsche Gesellschaft für Pädiatrische Hämatologie und Onkologie [German Society for Pediatric Hematology and Oncology]; LGG: low-grade glioma; SIOP: International Society for Pediatric Oncology).

**Abbildung 1.** Übersicht der laufenden Studie SIOP/GPOH LGG (GPOH: Deutsche Gesellschaft für Pädiatrische Hämatologie und Onkologie; LGG: niedrigmalignes Gliom; SIOP: Internationale Gesellschaft für Pädiatrische Onkologie).

[44] as compared to 48.7% and 88.7%, respectively, after first-line chemotherapy [73].

#### Chemotherapy

The effect of radiotherapy after chemotherapy has failed is unclear. In the series of Janss et al. [35], 46 children < 5 years of age received first-line chemotherapy. 17 children finally received radiotherapy because of progressive disease. Seven of 17 children who required radiation after chemotherapy have incurred a third progression, and the second progression-free survival rate was 29% at 10 years. It appears that this subset of patients represents a cohort with biologically more aggressive tumors and the additional question of whether chemotherapy renders the tumors radioresistant must be considered. By contrast, in an interim analysis of the SIOP LGG trial, a reduced efficacy after chemotherapy could not be observed [44]. In this study, 23 of 96 patients received radiotherapy when chemotherapy had failed. Although the follow-up was too short to draw reliable conclusions, the progression-free survival and overall survival rates did not differ from patients having received radiotherapy as first-line treatment (91.3% vs. 87.3% and 100% vs. 96.8%).

#### Dose-Response Effects

The optimum dose for radiation therapy in childhood low-grade glioma has not been well established [1, 17, 25, 31, 36,



38, 45, 52, 67] (Table 2). In children, no prospective randomized studies of radiotherapy dose/response have been performed. Retrospective analyses are rare, comprising small patient numbers and very heterogeneous dose prescriptions. Additionally, it can be assumed that the selection of dose prescriptions was strongly influenced by patient age, extent and site of tumor with a tendency to a lower dose in younger children with larger tumors (larger treatment portals), and consequently, the reported results were conflicting. Although it is difficult to define an adequate dose prescription, the recently recommended and generally accepted dose prescription ranges between 45 and 54 Gy in 1.8-Gy fractions depending on age at treatment, extent of disease, and location of tumor.

### Tumor Volume Response to Radiation

Radiographically determined response of optic gliomas to radiotherapy has not been well documented, because it has been assumed that low-grade gliomas in children are indolent and unresponsive to radiotherapy. Gould et al. [28] performed sequential CT scans in 20 children with optic glioma who had received radiotherapy. The authors found tumor regression in ten, a stable tumor in nine, and a treatment failure in one patient. Furuya et al. [20] reported serial CT evidence of decreasing size of a large chiasmal glioma over 2.5 years following irradiation with 51.4 Gy. In the analysis of Bataini et al. [3], a complete remission was observed 6 months after therapy in three of 57 patients. Grabenbauer et al. [31] described six of 25 patients who experienced a tumor regression after radiotherapy by > 50% seen on imaging studies. The response occurred between 6 and 24 months after completion of therapy. In the series of Fisher et al. [15] of 80 patients with a low-grade glioma, 19 patients with residual macroscopic lesions who received radiation therapy were selected for volumetric analysis of tumor response to treatment. The median time to response was 3.3 months. A  $\geq 25\%$  reduction in volume was seen in eight (43%) of the 19 patients. A  $\geq 50\%$  reduction was noted in five (26%) of the patients. A complete response was demonstrated at 7, 12, and 15 months, and 5 years, respectively, in four patients (21%). Tao et al. [69] observed a great variability in time

to maximal response. Stable disease as assessed on imaging was seen in 56% over the whole period of follow-up. It took a median time of 62 months until maximal response in terms of a partial remission (in 24% of cases) and a complete remission (16%), which was in sharp contrast to the rapid clinical response. In four of these patients, a documented complete remission with normal visual pathways was noted > 10 years after treatment.

Bakardjiev et al. [2] followed patients with MRI at close time intervals between 3 and 26 months after stereotactic fractionated radiotherapy with a total dose between 52.2 and 60 Gy. Twelve of 28 patients developed an increased size of the lesions between 9 and 12 months after radiotherapy, which was not accompanied by clinical symptoms. The changes resolved or decreased by 15–21 months.

### Treatment Fields

In childhood low-grade gliomas, local failure is the predominant feature in progressive or recurrent disease, and leptomeningeal spread is a rare event (< 5%) [56]. This implies that treatment fields encompassing the tumor are appropriate. Today, computer-assisted (preferable 3-D) treatment planning is mandatory in order to reduce possible acute morbidity and late sequelae. This technique allows a 30–40% reduction in the volume of normal brain tissue exposed to high-dose irradiation.

**Table 2.** Progression-free survival (PFS) in children and adults with low-grade glioma. Dose-response relationship. n.m.: not mentioned; n.s.: not significant.

**Tabelle 2.** Progressionsfreies Überleben (PFS) bei Kindern und Erwachsenen mit niedrigmalignen Gliomen. Dosis-Wirkungs-Beziehung. n.m.: nicht erwähnt; n.s.: nicht signifikant.

Author	Patients	Total dose	Fractionated dose	PFS (5 years)	PFS (10 years)	p-value
Karim et al., 1996 [38]	171	45.0 Gy	1.8 Gy	47%	Not reached	n.s.
	172	59.4 Gy		50%		
Montgomery et al., 1977 [52]	7	$\leq 42$ Gy	n.m.	Overall 43%	n.m.	n.m.
	9	$\geq 50$ Gy		100%		
Sung, 1982 [67]	13	35–45 Gy	n.m.	Relapse rate: 11/13	n.m.	n.m.
	29	50–60 Gy		8/29		
Alvord & Lofton, 1988 [1]	52	> 45.0 Gy	n.m.	80%	65%	n.m.
	62	< 45.0 Gy		65%	55%	
Flickinger et al., 1988 [17]	12	> 45.0 Gy	Calculation according to nominal standard dose	100%		0.045
	12	< 45.0 Gy		75%		
Kovalic et al., 1990 [45]	3	< 40.0 Gy	n.m.	0	0%	< 0.0001
	30	> 40.0 Gy		90%	79%	
Garcia et al., 1990 [25]	8	< 40 Gy	n.m.	4/8 recurred	n.m.	n.m.
	17	$\geq 40$ Gy		2/17 recurred		
Jenkin et al., 1993 [36]	19	> 50.0 Gy	n. m.	88%	88%	0.37, n.s.
	15	< 50.0 Gy		72%	57%	
Grabenbauer et al., 2000 [31]	9	44–45 Gy	1.6–2.0 Gy	87%	36%	0.04
	16	45.1–60 Gy		90%	85%	

tion as compared to conventional 2-D treatment planning [42]. Debus et al. [9] used 3-D conformal external-beam radiotherapy in ten patients. The clinical target volume (CTV) included the visible tumor in CT and MRI plus 5 mm, the planning target volume (PTV) consisted of the CTV plus 2 mm safety margin. No treatment failure was observed suggesting that limiting the high-dose volume did not cause an increase in marginal or out-of-field failure rate. Merchant et al. [49] also employed fractionated conformal radiotherapy in 38 pediatric patients with low-grade glioma. The CTV was more generous and extended 1.0 cm beyond the gross tumor volume (GTV) as visible on MRI. The PTV encompassed the CTV with an additional 5-mm safety margin. Three patients failed within the CTV and one immediately outside. Saran et al. [60] defined the PTV as the visible tumor plus a safety margin of 5–10 mm. Only one out of 14 patients progressed at the primary tumor site.

### **New Approaches in Radiotherapy** **Stereotactic Radiotherapy**

Stereotactic irradiation techniques in conjunction with rigid head fixation systems comprising single high-dose delivery (“radiosurgery”), fractionated convergence therapy, and fractionated 3-D conformal therapy are well established in adults, but data for childhood central nervous system malignancies, in particular low-grade glioma, are scarce. Preliminary data reveal low acute toxicity and promising results in recurrent tumors as well as in primary treatment [2, 4, 9, 12, 19, 22, 29, 34, 47, 65, 66].

*Stereotactic Convergence Therapy (“Radiosurgery”).* Since survival rates have correlated with the degree of resection suggesting the necessity for radical local treatment [18, 55], long-term outcome might be improved if radiosurgery can convert a subtotal excision to a complete excision. Application may be restricted to selected hemispheric lesions < 5 cm in order to limit the risk for serious morbidity due to increasing dose inhomogeneity combined with an increased exposure of normal brain to high doses. Additionally, the large single fraction generally employed may induce necrosis and this often precludes the use of this technique in functionally significant areas within the visual pathway.

Grabb et al. [29] investigated the role of radiosurgery in a series of 25 children, 13 of whom had pilocytic and low-grade astrocytomas (Table 3). Of the latter, eleven had received fractionated irradiation before stereotactic radiosurgery. During a median follow-up of 21 months, eleven of the 13 children with benign glial neoplasms had tumor control, and all of them have remained alive. In the series of Ganz et al. [22], eight tumors in seven patients were treated with “gamma-knife radiosurgery”. In one child a complete remission on imaging could be obtained, four showed a reduction in size, three were stable at a mean follow-up of 21 months. These results were confirmed by Somaza et al. [65]. Since patients treated in these series represent a very inhomogeneous cohort, due to often slow

growth rates of low-grade glioma and possible late toxicity, it is necessary to evaluate a much longer follow-up, before a definite conclusion regarding the role of radiosurgery will be reached.

*Fractionated Stereotactic Convergence Therapy.* Stereotactic fractionated radiotherapy combines the advantages of the precise “focal approach” of stereotactic radiosurgery with the benefits of fractionation of conventional external-beam irradiation. Souhami et al. [66] used 6.3- to 7.5-Gy fractions on alternate days up to 37.8 and to 45.5 Gy in 2 weeks in 15 patients, including several children, treated at recurrence or primary presentation of astrocytoma, craniopharyngeoma or chordoma. Early results were encouraging, as were those by Dunbar et al. [12] (Table 3). Freeman et al. [19] reported on ten patients with previously untreated primary brain tumors who were managed with stereotactic hypofractionated convergence radiotherapy using rigid head fixation. Clinical and radiologic improvement was achieved in all patients, as well as an almost complete remission in two patients at a follow-up between 5 and 47 months. In the subsequent series from the same institution by Benk et al. [4], the outcome in eight children with low-grade astrocytoma was reported. The actuarial 5-year overall survival rate was 100%, and the progression-free survival rate was 60%.

*Fractionated Conformal Radiotherapy.* Radiotherapy using multiple static fields conformed to the irregular shape of glioma of the optic pathway achieves a maximum dose within the lesion while sparing normal surrounding structures. In contrast to convergence therapy, tumors of virtually all sizes and shapes can be treated, and the geometric accuracy is equivalent [41, 75]. At present, however, clinical data are scarce for childhood low-grade glioma. Debus et al. [9] treated ten patients with optic gliomas. The median prescribed dose was 52.4 Gy with daily fractions between 1.6 and 2.0 Gy. All patients remained free from local tumor progression during a follow-up period of 12–72 months. Merchant et al. [49] treated 38 children with fractionated conformal radiotherapy between 54 and 59.4 Gy, 1.8 Gy fractionated dose. The patients were followed for a median of 17 months, and four experienced recurrent disease at the primary tumor site. Acute toxicity was reported to be low. Saran et al. [60] treated 14 children and achieved a 3-year local progression-free survival and overall survival rate of 87% and 100%, respectively, compared with 89% and 98% for a historic control treated with conventional radiotherapy. Four of twelve children with neurologic deficits improved, and five remained stable.

### **Proton Therapy**

The major advantage of proton therapy over conventional radiation techniques is the high degree of dose conformity around the tumor that can be achieved, since protons have no exit dose beyond the target. Only one report has been published. The working group of Loma Linda treated 27 pediatric patients with progressive or recurrent gliomas at various sites

**Table 3.** Stereotactic fractionated, proton therapy and high single-dose radiotherapy (“radiosurgery”) in childhood low-grade gliomas (hemispheric and midline location).**Tabelle 3.** Stereotaktische fraktionierte und Einzelbestrahlung („Radiochirurgie“) bei niedrigmalignen Gliomen im Kindesalter (hemisphärische und Mittellinienlokalisation).

Author	Technique	Patients	Outcome	Follow-up
Dunbar et al., 1994 [12]	Fractionated convergence therapy 5 × 1.8–2.0 Gy/45–54 Gy + dose escalation 60 Gy	11 (initial RT) 9 (recurrence)	No acute side effects 1 CR, 19 PR/SD Overall survival 100%	16 months
Ganz et al., 1994 [22]	High single dose (“radiosurgery”) Dose : 12 Gy	7 pat. 8 tumors	No acute side effects 1 CR, 4 PR, 3 SD Overall survival 100%	21 months
Grabb et al., 1996 [29]	High single dose (“radiosurgery”) Dose : 11–20 Gy	13	4 transient edemas 4 CR, 5 PR, 2 SD, 2 PD Overall survival 100%	21 months
Somaza et al., 1996 [65]	High single dose (“radiosurgery”) Dose: 15 Gy	9	Progression-free survival 100%	
Overall survival 100%				
Lim & Leem, 1996 [47]	High single dose (“radiosurgery”) Dose: 12–14.4 Gy	2	No side effects Decrease in tumor size and improvement of vision in both patients	24–43 months
Bakardjiev et al., 1996 [2]	Fractionated convergence therapy 5 × 1.8–2.0 Gy/52.2–60.0 Gy	28	Overall survival 100% 15 pat. decreased tumor size 1 pat. stable tumor size 13 pat. increased tumor size (transient [15–21 months])	24 months
Benk et al., 1999 [4]	Hypofractionated convergence therapy Median total dose 39 Gy (18.0–42.0 Gy) in 6–10 fractions	8	1 edema, 1 edema + tumor necrosis, 1 tumor necrosis 5-year progression-free survival 60% Overall survival 100%	42 months
Debus et al., 1999 [9]	Fractionated conformal radiotherapy Median total dose 52.4 Gy/1.6–2.0 Gy fractionated dose	10	Progression-free survival at 5 years 90% Overall survival 100% No acute toxicity	12–72 months
Merchant et al., 2002 [49]	Fractionated conformal radiotherapy Median total dose 54–59.4 Gy/1.8 Gy fractionated dose	38	4 failures (3 within CTV and one immediately outside)	17 months (3–44 months)
Saran et al., 2002 [60]	Fractionated conformal radiotherapy Median total dose 50–55 Gy in 30–33 fractions	14	Progression-free survival at 3 years 87% Overall survival 100%	33 months (2–53 months)
Hug et al., 2002 [34]	Proton therapy 50.4–63.0 CGE (Cobalt Gray Equivalent), 1.8 Gy fractionated dose	Total 27 pat. Hemispheric 7 pat. Dienceph. 15 pat. Brain stem 5 pat.	Local control Hemispheric 71% Dienceph. 87% Brain stem 60%	Survival rate 86% 93% 60%

[34] (Table 3). Target doses were between 50.4 and 63.0 CGE (Cobalt Gray Equivalent) at 1.8 Gy per fraction. At a mean follow-up period of 3.3 years, six patients experienced local failure and four died of disease. By anatomic sites, these data translated into rates of local control and survival of 87%/93% for midline tumors, 71%/86% for hemispheric tumors, and 60%/60% for brain stem tumors. The authors stated that their results were very encouraging especially for larger, irregularly

shaped tumors along the visual pathway, where dose conformity is of particular importance.

### Brachytherapy

Interstitial brachytherapy is a useful alternative in selected cases. The purpose of interstitial brachytherapy is to deliver a focal necrotizing radiation dose within the tumor while sparing normal surrounding tissue. There is a steep dose gradient at the



periphery thereby leaving a high cumulative dose around the implanted radioactive seeds, most commonly Iodine-125. The largest series of interstitial brachytherapy in childhood and adult low-grade glioma was published by Kreth et al. [46]. A total of 455 patients with low-grade glioma were treated by using  $^{125}\text{I}$  either as permanent or temporary implants. The 5- and 10-year survival rates in 97 patients with pilocytic astrocytoma were 85% and 83% and in patients with WHO grade II astrocytomas (250 patients) 61% and 51%, respectively. 124 of 455 patients were children and adolescents, 54 had a WHO grade II glioma, 70 a pilocytic astrocytoma. A 5-year survival rate of 84% was obtained in astrocytoma WHO II and 90% in pilocytic astrocytomas. Clinical stability was reported to be maintained throughout the survival time in all children. However, the data were not specifically analyzed with respect to the pediatric cohort within this series. It seems that small, circumscribed tumors with a diameter of < 4 cm in locations other than the optic nerve and chiasm are preferred cases for interstitial radiosurgery.

#### Radiotherapy in Recurrent Disease

Reoperation and, recently, chemotherapy are generally accepted as the mainstay of any salvage treatment in recurrent glioma. There are very few cases in the literature in which reirradiation was performed, the major demand being a sparing of normal tissue thus requiring a precise and focused radiotherapy. Stereotactic approaches may be useful, but experience of this endeavour is limited to case reports. Grabb et al. [29] treated one child using radiosurgery at a reduced dose of 12 Gy to the tumor margin. Despite treatment, tumor progression continued and was evident on imaging 6 months after therapy. Pollack et al. [55] reported on a circumscribed lesion at the margin of the initial radiation field that was treated with radiosurgery. The tumor regressed completely, and the child remained free of further progression 48 months after radiosurgery. Alvord & Lofton [1] analyzed 69 patients with gliomas of the optic pathway who underwent a second treatment. 32 of the patients received a second course of radiotherapy. All patients were < 20 years of age. Failures occurred more rapidly after the second treatment. In the report of Weiss et al. [76], one patient was reirradiated 8 years after primary treatment because of recurrent disease at a dose prescription of 30 Gy given in 3 weeks. He was reported to remain alive and well at 20 years with stable, although poor vision.

#### Disseminated Low-Grade Glioma

The occurrence of metastatic disease from pilocytic astrocytoma is a rare event, estimated to occur in 4% of cases. With improvements in neuroimaging, this phenomenon is being identified with increasing frequency, and as a consequence, craniospinal irradiation needs to be considered for these patients. In the report of Pollack et al. [56], 76 patients with low-grade astrocytomas were reviewed who had a biopsy-proven tumor diagnosed between 1982 and 1991. Three of them were found to have disseminated disease either at presentation or

during the course of the disease. All three patients had a pilocytic astrocytoma. In one child craniospinal irradiation was administered with 30 Gy to the spinal canal followed by a boost to the thoracolumbosacral spine with 14 Gy. The whole brain received a total dose of 60 Gy. A hyperfractionated schedule was performed administering 1 Gy per fraction twice daily. 30 months after treatment, no evidence of recurrence or persistent tumor was detectable on MRI. The patient's endocrine function was normal, and school performance remained excellent at 5½ years of age. The two other children received various treatments consisting of chemotherapy and involved-field irradiation at a dose prescription between 45 and 54 Gy. At last follow-up, they were in continuous complete remission. Late effects were acceptable. Mishima et al. [51] reported the case of a 6-year-old boy who underwent surgery followed by radiotherapy of the affected regions of the brain and spinal canal. The child was free of recurrence at a follow-up of 6 years after treatment. The question remains open as to whether to proceed with radiotherapy or chemotherapy.

#### Conclusions

Treatment of childhood low-grade glioma is still a challenging issue in pediatric neurooncology. Surgery is widely accepted as the treatment of choice in hemispheric and cerebellar low-grade gliomas that can be safely resected. The role of surgery in gliomas of the visual pathway has to be seen in the light of preservation of neurologic and visual function and is therefore limited to biopsy in the majority of cases to obtain histologic confirmation [26, 48, 68]. If imaging is sufficient for diagnosis, a biopsy is not necessary [26, 48, 68]. In tumors confined to the optic nerve, in a blind eye radical surgery achieves cure and can be justified if cosmetically acceptable [11, 32].

The timing of postoperative radiotherapy in childhood hemispheric and cerebellar low-grade glioma now appears clearer following a report from the EORTC study in adults showing that an improvement in progression-free but not overall survival is obtained after immediate postoperative radiotherapy [39], a fact which can also be seen in children [16]. However, a reliable identification of prognostic factors supporting the use of immediate postoperative radiotherapy is still lacking for children [16]. Low-grade gliomas of the supratentorial midline (visual pathway) are a separate issue. Visual function is an important measure of treatment success. Visual improvement is rarely seen with an observation policy. A clinically relevant success rate in maintaining or improving vision is only possible, if treatment is initiated before severe visual damage has occurred. Therefore, documented visual deterioration is a major indication to initiate radiation therapy promptly. Approximately 90% of patients experience either improvement or stabilization of visual function (Table 1). However, a clear description of visual function in the literature is often lacking requiring the introduction of reproducible and comparable neuroophthalmologic methods to precisely assess visual function, especially in the very young.

Presently, it is recommended to employ radiotherapy for patients with progressive disease only, regardless of tumor location [16, 26, 48]. In younger children (e.g., < 5 years old), the role of chemotherapy is under investigation (SIOP/GPOH LGG trial), deferring radiotherapy until further progression.

Tumors located in the anterior visual pathway have a better prognosis than hypothalamic tumors [3, 36, 45, 58, 77]. It appears that the latter benefit most from radiotherapy [3, 36, 77]. The impact of NF on clinical outcome is unclear. In some series, NF appears to be associated with a better survival and a better response rate to radiotherapy as compared to the absence of NF [6, 31, 35, 36, 45].

Although data for a clear dose-response relationship are lacking, there is consent today to apply total doses between 45 and 54 Gy (1.8 Gy fractionated dose) depending on the location and extent of tumors as well as age at treatment [1, 17, 31, 32, 52]. Low-grade gliomas in children can demonstrate shrinkage on radiographic studies in response on radiotherapy, but such shrinkage is not directly related to tumor control or improvement of symptoms. Treatment-related changes on MRI might be misleading and should be distinguished from tumor progression [2].

Modern treatment techniques based on fractionated 3-D (conformal) techniques have become standard today to precisely treat tumors of the visual pathway while sparing normal tissue. The currently recommended standardized approach is based on the ICRU 50/62 Report. The CTV encompasses the visible tumor as seen on MR (T2-weighted images) with an additional margin between 0.5 and 1.0 cm considering anatomic borders [9, 49, 60]. It can be concluded that normal tissue sparing through the use of advanced radiation therapy treatment planning and delivery techniques should be beneficial to pediatric patients if the rate and patterns of failure are similar to conventional techniques at a longer follow-up. Proton therapy is excellent in achieving high dose conformity, however, the access to this modality is limited [34]. Possibly, the recent advances in intensity-modulated radiotherapy will be able to achieve a similar dose conformity even in larger tumors. Brachytherapy might be a useful alternative, but is applicable only in selected tumors [46]. Likewise, radiosurgery is playing a limited role as first-line treatment [22, 29, 47]. Reirradiation might be feasible in selected cases by using modern treatment techniques [1, 55, 76].

The role of radiation therapy in disseminated low-grade glioma is largely unknown and mandates further investigations [51, 56].

Today, prospective trials in childhood brain tumors are indispensable to assess the role of radiotherapy both in terms of survival and late effects [43, 59, 72]. Based on these experiences, the following aims will be addressed in the future SIOP LGG 2003 radiotherapy protocol:

a) utilizing modern treatment techniques to reduce the integral radiation dose given to normal tissue compared with the previous protocol;

- b) to record and monitor the integral dose to tumor and normal tissue as a basis for future assessment of late effects and quality of life of long-term survivors (see part II);
- c) to assess response of tumor and clinical symptoms to radiotherapy;
- d) to assess the pattern of relapse when using modern treatment techniques;
- e) to assess the role of craniospinal irradiation in children with disseminated low-grade glioma (phase II trial).

## References

1. Alvord EC Jr, Lofton S. Gliomas of the optic nerve and chiasm. Outcome by patients' age, tumor site, and treatment. *J Neurosurg* 1988;68:85–98.
2. Bakardjiev AI, Barnes PD, Goumnerova LC, Black PM, Scott RM, Pomeroy SL, Billett A, Loeffler JS, Tarbell NJ. Magnetic resonance imaging changes after stereotactic radiation therapy for childhood low grade astrocytoma. *Cancer* 1996;78:864–73.
3. Bataini JP, Delanian S, Ponvert D. Chiasmal gliomas: results of irradiation management in 57 patients and review of literature. *Int J Radiat Oncol Biol Phys* 1991;21:615–23.
4. Benk V, Clark BG, Souhami L, Algan O, Bahary J, Podgorsak EB, Freeman CR. Stereotactic radiation in primary brain tumors in children and adolescents. *Pediatr Neurosurg* 1999;31:59–64.
5. Brand NW, Hoover SV. Optic glioma in children. Review of 16 cases given megavoltage radiation therapy. *Childs Brain* 1979;5:459–66.
6. Cappelli C, Grill J, Raquin M, Pierre-Kahn A, Lellouch-Tubiana A, Terrier-Lacombe MJ, Habrand JL, Couanet D, Brauner R, Rodriguez D, Hartmann O, Kalifa C. Long-term follow up of 69 patients treated for optic pathway tumours before the chemotherapy era. *Arch Dis Child* 1998;79:334–8.
7. Chan MY, Foong AP, Heisey DM, Harkness W, Hayward R, Michalski A. Potential prognostic factors of relapse-free survival in childhood optic pathway glioma: a multivariate analysis. *Pediatr Neurosurg* 1998;29:23–8.
8. Danoff BF, Kramer S, Thompson N. The radiotherapeutic management of optic nerve gliomas in children. *Int J Radiat Oncol Biol Phys* 1980;6:45–50.
9. Debus J, Kocogoncu KO, Hoss A, Wenz F, Wannenmacher M. Fractionated stereotactic radiotherapy (FSRT) for optic glioma. *Int J Radiat Oncol Biol Phys* 1999;44:243–8.
10. Dirven CMF, Mooij JJA, Molenaar WM. Cerebellar pilocytic astrocytoma: a treatment protocol based upon analysis of 73 cases and review of the literature. *Childs Nerv Sys* 1997;13:17–23.
11. Dosoretz DE, Blitzer PH, Wang CC, Linggood RM. Management of glioma of the optic nerve and/or chiasm: an analysis of 20 cases. *Cancer* 1980;45:1467–71.
12. Dunbar SF, Tarbell NJ, Kooy HM, Alexander E III, Black PM, Barnes PD, Goumnerova L, Scott RM, Pomeroy SL, La Vally B. Stereotactic radiotherapy for pediatric and adult brain tumors: preliminary report. *Int J Radiat Oncol Biol Phys* 1994;30:531–9.
13. Dutton JJ. Gliomas of the anterior visual pathway. *Surv Ophthalmol* 1994;38:427–52.
14. Erkal HS, Serin M, Cakmak A. Management of optic pathway and chiasmatic-hypothalamic gliomas in children with radiation therapy. *Radiother Oncol* 1997;45:11–5.
15. Fisher BJ, Bauman GS, Leighton CE, Stitt L, Cairncross JG, MacDonald DR. Low-grade gliomas in children: tumor volume response to radiation. *J Neurosurg* 1998;88:969–74.
16. Fisher BJ, Leighton CE, Vujovic O, MacDonald DR, Stitt L. Results of a policy of surveillance alone after surgical management of pediatric low-grade gliomas. *Int J Radiat Oncol Biol Phys* 2001;51:704–10.
17. Flickinger JC, Torres C, Deutch M. Management of low-grade gliomas of the optic nerve and chiasm. *Cancer* 1988;61:635–62.
18. Forsyth PA, Shaw EG, Scheithauer BW, O'Fallon JR, Layton DD Jr, Katzman JA. Supratentorial pilocytic astrocytoma. A clinicopathologic, prognostic, and flow cytometric study of 51 patients. *Cancer* 1993;72:1335–42.

19. Freeman CR, Souhami L, Caron JL, Villemure JG, Olivier A, Montes J, Farmer JP, Podgorsak EB. Stereotactic external beam irradiation in previously untreated brain tumors in children and adolescents. *Med Pediatr Oncol* 1994;22:173–80.
20. Furuya Y, Uemura R, Ryu H, Nakajima S, Sato K, Yokoyama T, Kaneko M. Optic glioma decreasing in size after irradiation. *J Child Neurol* 1986;1:173–5.
21. Gajjar A, Sanford RA, Heideman R, Jenkins JJ, Walter A, Li Y, Langston JW, Muhlbauer M, Boyett JM, Kun LE. Low-grade astrocytoma: a decade of experience at St. Jude Children's Research Hospital. *J Clin Oncol* 1997;15:2792–9.
22. Ganz JC, Smievoll AI, Thorsen F. Radiosurgical treatment of gliomas of the diencephalons. *Acta Neurochir (Wien)* 1994;62:Suppl:62–6.
23. Garcia DM, Fulling KH, Marks JE. The value of radiation therapy in addition to surgery for astrocytomas of adult cerebrum. *Cancer* 1985;55:919–27.
24. Garcia DM, Latifi HR, Simpson JR, Picker S. Astrocytomas of the cerebellum in children. *J Neurosurg* 1989;71:661–4.
25. Garcia DM, Marks JE, Latifi HR, Kliefoth AB. Childhood cerebellar astrocytomas: is there a role for postoperative irradiation? *Int J Radiat Oncol Biol Phys* 1990;18:815–8.
26. Garvey M, Packer RJ. An integrated approach to the treatment of chiasmatic-hypothalamic gliomas. *J Neurooncol* 1996;28:167–83.
27. Gjerris F, Klinken L. Long term prognosis in children with benign cerebellar astrocytoma. *J Neurosurg* 1978;49:179–84.
28. Gould RJ, Hilal SK, Chutorian AM. Efficacy of radiotherapy in optic gliomas. *Pediatr Neurol* 1987;3:29–32.
29. Grabb PA, Lunsford LD, Albright AL, Kondziolka D, Flickinger JC. Stereotactic radiosurgery for glial neoplasms of childhood. *Neurosurgery* 1996;38:696–701.
30. Grabenbauer GG, Roedel CM, Paulus W, Ganslandt O, Schuchardt U, Buchfelder M, Schrell U, Fahlbusch R, Huk WJ, Sauer R. Supratentorial low-grade glioma: results and prognostic factors following postoperative radiotherapy. *Strahlenther Onkol* 2000;176:259–64.
31. Grabenbauer G, Schuchardt U, Buchfelder M, Rodel C, Gusek G, Marx M, Doerr H, Fahlbusch R, Huk W, Wenzel D, Sauer R. Radiation therapy of optico-hypothalamic gliomas (OHG): radiographic response, vision and late toxicity. *Radiat Oncol* 2000;54:239–54.
32. Horwich A, Bloom HJG. Optic gliomas: radiation therapy and prognosis. *Int J Radiat Oncol Biol Phys* 1985;11:1067–79.
33. Hoyt WF, Baghdassarian SA. Optic glioma of childhood. Natural history and rationale for conservative management. *Br J Ophthalmol* 1969;53:793–8.
34. Hug EB, Muentner MW, Archambeau JO, DeVries A, Liwnicz B, Loredano LN, Grove RI, Slater JD. Conformal proton radiation therapy for pediatric low-grade astrocytoma. *Strahlenther Onkol* 2002;178:10–7.
35. Janss AJ, Grundy R, Cnaan A, Savino PJ, Packer RJ, Zackai EH, Goldwein JW, Sutton LN, Radcliffe J, Molloy PT. Optic pathway and hypothalamic/chiasmatic gliomas in children younger than age 5 years with a 6-year follow-up. *Cancer* 1995;75:1051–9.
36. Jenkin D, Angyalfi S, Becker L, Berry M, Buncic R, Chan H, Doherty M, Drake J, Greenberg M, Hendrick B. Optic glioma in children: surveillance, resection, or irradiation? *Int J Radiat Oncol Biol Phys* 1993;25:215–25.
37. Kalifa C, Ernest C, Rodary C, Sarrazin D, Bloch Michel E, Lemerle J. Optic glioma in children. A retrospective study of 57 cases treated by irradiation. *Arch Fr Pediatr* 1981;38:309–13.
38. Karim AB, Maat B, Hatlevoll R, Menten J, Rutten EH, Thomas DG, Mascarenhas F, Horiot JC, Parvinen LM, van Reijn M, Jager JJ, Fabrini MG, van Alphen AM, Hamers HP, Gaspar LE, Noordman E, Pierart M, van Gleebeke M. A randomised trial on dose-response in radiation therapy of low-grade glioma: European Organization for Research and Treatment of Cancer (EORTC) Study 22844. *Int J Radiat Oncol Biol Phys* 1996;36:549–56.
39. Karim AB, Afra D, Cornu P, Bleehan N, Schraub S, De-Witte O, Darcel F, Stenning S, Pierart M, Van-Glabbeke M. Randomized trial on the efficacy of radiotherapy for cerebral low-grade glioma in the adult: European Organization for Research and Treatment of Cancer Study 22845 with the Medical Research Council Study BR04: an interim analysis. *Int J Radiat Oncol Biol Phys* 2002;52:316–24.
40. Kortmann RD. Long-term results after conservative surgery of hypothalamic/chiasmatic astrocytomas in childhood. *Strahlenther Onkol* 1996;172:280–1.
41. Kortmann RD, Becker G, Perelmouter J, Buchgeister M, Meisner C, Bamberg M. Geometric accuracy of field alignment in fractionated stereotactic conformal radiotherapy of brain tumors. *Int J Radiat Oncol Biol Phys* 1999;43:921–6.
42. Kortmann RD, Jeremic B, Bamberg M. Radiotherapy in management of low grade glioma. In: Petrowich Z, Brady LW, Apuzzo ML, Bamberg M, eds. Combined modality therapy for central nervous system tumours. Berlin–Heidelberg–New York: Springer, 2000:317–26.
43. Kortmann RD, Kuhl J, Timmermann B, Calaminus G, Dieckmann K, Wurm R, Sorensen N, Urban C, Gobel U, Bamberg M. Aktuelle und zukünftige Strategien in der interdisziplinären Therapie von Medulloblastomen, supratentoriellen PNET und intrakraniellen Keimzelltumoren im Kindesalter [Current and future strategies in interdisciplinary treatment of medulloblastomas, supratentorial PNET (primitive neuroectodermal tumors) and intracranial germ cell tumors in childhood]. *Strahlenther Onkol* 2001;177:447–61.
44. Kortmann RD, Zanetti I, Mueller S, Taylor RE, Scarlallo G, Perilongo G, Walker DA, Gnekow AK, Garre ML. Radiotherapy in low grade glioma: an interim analysis of SIOP low grade glioma study. IXth Symposium Pediatric NeuroOncology, San Francisco 2000.abstract.
45. Kovalic JJ, Grigsby PW, Shepard MJ, Fineberg BB, Thomas PR. Radiation therapy for gliomas of the optic nerve and chiasm. *Int J Radiat Oncol Biol Phys* 1990;18:927–32.
46. Kreth FW, Faist M, Warne PC, Rossner R, Volk B, Ostertag CB. Interstitial radiosurgery of low-grade gliomas. *J Neurosurg* 1995;82:418–29.
47. Lim YJ, Leem W. Two cases of gamma knife radiosurgery for low-grade optic chiasm glioma. *Stereotact Funct Neurosurg* 1996;66:Suppl 1:174–83.
48. Listernik R, Louis DN, Packer RJ, Gutmann DH. Optic pathway gliomas in children with neurofibromatosis I: consensus statement from the NF1 Optic Pathway Glioma Task Force. *Ann Neurol* 1997;41:143–9.
49. Merchant TE, Zhu Y, Thompson SJ, Sontag MR, Heideman RL, Kun LE. Preliminary results from a phase II trial of conformal radiation therapy for pediatric patients with localised low-grade astrocytoma and ependymoma. *Int J Radiat Oncol Biol Phys* 2002;52:325–32.
50. Michaelis J, Kaletsch U, Kaatsch P. Epidemiology of childhood brain tumors. *Zentralbl Neurochir* 2000;61:80–7.
51. Mishima K, Nakamura M, Nakamura H, Nakamura O, Funata N, Shitara N. Leptomeningeal dissemination of cerebellar pilocytic astrocytoma. Case report. *J Neurosurg* 1992;77:788–91.
52. Montgomery AB, Griffin T, Parker RG, Gerdes AJ. Optic nerve glioma: the role of radiation therapy. *Cancer* 1977;40:2079–80.
53. Packer RJ, Savino PJ, Bilaniuk LT, Zimmerman RA, Schatz NJ, Rosenstock JG, Nelson DS, Jarrett PD, Bruce DA, Schut L. Chiasmatic gliomas of childhood. A reappraisal of natural history and effectiveness of cranial irradiation. *Childs Brain* 1983;10:393–403.
54. Pierce SM, Barnes PD, Loeffler JS, McGinn C, Tarbell NJ. Definitive radiation therapy in the management of symptomatic patients with optic glioma. Survival and long-term effects. *Cancer* 1990;65:45–52.
55. Pollack IF, Claassen D, al Shboul Q, Janosky JE, Deutch M. Low-grade gliomas of the cerebral hemispheres in children: an analysis of 71 cases. *J Neurosurg* 1995;82:536–47.
56. Pollack IF, Hurtt M, Pang D, Albright AL. Dissemination of low-grade intracranial astrocytomas in children. *Cancer* 1994;73:2869–78.
57. Rodriguez LA, Edwards MS, Levin VA. Management of hypothalamic gliomas in children: an analysis of 33 cases. *Neurosurgery* 1990;26:242–6.
58. Rush JA, Younge BR, Campbell RJ, MacCarty CS. Optic glioma. Long-term follow-up of 85 histopathologically verified cases. *Ophthalmology* 1982;89:1213–9.
59. Sack H. Intellektuelle Leistungen von Kindern nach Ganzhirnbestrahlung und Chemotherapie [Intellectual outcome in children after total brain irradiation and chemotherapy]. *Strahlenther Onkol* 2002;178:50.
60. Saran FH, Baumert BG, Khoo VS, Adams EJ, Garre ML, Warrington AP, Brada M. Stereotactically guided conformal radiotherapy for progressive low-grade gliomas of childhood. *Int J Radiat Oncol Biol Phys* 2002;53:43–51.
61. Schneider JH, Raffel C, McComb JG. Benign cerebellar astrocytomas of childhood. *Neurosurgery* 1992;30:58–63.
62. Shaw EG, Dumas-Duport C, Scheithauer BW, Gilbertson DT, O'Fallon JR, Earle JD, Laws ER Jr, Okazaki H. Radiation therapy in the management of low-grade supratentorial astrocytomas. *J Neurosurg* 1989;70:853–61.

63. Shibamoto Y, Kitakabu Y, Takahashi M, Yamashita J, Oda Y, Kikuchi H, Abe M. Supratentorial low-grade astrocytoma. Correlation of computed tomography findings with effect of radiation therapy and prognostic variables. *Cancer* 1993;72:190–5.
64. Smoots DW, Geyer JR, Lieberman DM, Berger MS. Predicting disease progression in childhood cerebellar astrocytoma. *Child Nerv Syst* 1998;14: 636–48.
65. Somaza SC, Kondziolka D, Lunsford LD, Flickinger JC, Bissonette DJ, Al-bright AL. Early outcomes after stereotactic radiosurgery for growing pilocytic astrocytomas in children. *Pediatr Neurosurg* 1996;25:109–15.
66. Souhami L, Olivier A, Podgorsak EB, Villemure JG, Pla M, Sadikot AF. Fractionated stereotactic radiation therapy for intracranial tumors. *Cancer* 1991;68:2101–8.
67. Sung DI. Suprasellar tumors in children: a review of clinical manifestations and managements. *Cancer* 1982;50:1420–5.
68. Sutton LN, Molloy PT, Sernyak H, Goldwein J, Phillips PL, Rorke LB, Moshang T Jr, Lange B, Packer RJ. Long-term outcome of hypothalamic/charismatic astrocytomas in children treated with conservative surgery. *J Neurosurg* 1995;83:583–9.
69. Tao ML, Barnes PD, Billett AL, Leong T, Shrieve DC, Scott RM, Tarbell NJ. Childhood optic chiasm gliomas: radiographic response following radiotherapy and long-term clinical outcome. *Int J Radiat Oncol Biol Phys* 1997;39:579–87.
70. Taveras J, Lester A, Wood E. The value of radiation therapy in the management of glioma of the optic nerves and chiasma. *Radiology* 1956;66:518–28.
71. Tenny RT, Laws ER Jr, Younge BR, Rush JA. The neurosurgical management of optic glioma. Results of 104 patients. *J Neurosurg* 1982;57:452–8.
72. Timmermann B, Kortmann RD, Kuhl J, Willich N, Bamberg M. Die interdisziplinäre Therapie von Ependymomen im Kindesalter [Interdisciplinary therapy of childhood ependymomas]. *Strahlenther Onkol* 2002;178:469–79.
73. Wallner KE, Gonzalez M, Sheline GE. Treatment of oligodendrogliomas with or without postoperative irradiation. *J Neurosurg* 1988;68:684–8.
74. Walker DA, Taylor RE, Perilongo G, Zanetti I, Gnekow AK. Vincristine (VCR) carboplatin (CBDCA) in low grade glioma: an interim report of the International Consortium on Low Grade Glioma (ICLGG). IXth Symposium Pediatric NeuroOncology, San Francisco 2000.abstract.
75. Warrington AP, Laing RW, Brada M. Quality assurance in fractionated stereotactic radiotherapy. *Radiother Oncol* 1994;30:239–46.
76. Weiss L, Sagerman RH, King GA, Chung CT, Dubow RL. Controversy in the management of optic nerve glioma. *Cancer* 1987;59:1000–4.
77. Wong JY, Uhl V, Wara WM, Sheline GE. Optic gliomas. A reanalysis of the University of California, San Francisco experience. *Cancer* 1987;60: 1847–55.

**Address for Correspondence**

Rolf-Dieter Kortmann, MD  
Department of Radiation Oncology  
University of Tübingen  
Hoppe-Seyler-Straße 3  
72076 Tübingen  
Germany  
Phone (+49/7071) 29-82165, Fax -5894  
e-mail: rdkortma@med.uni-tuebingen.de